CHAPTER

56 The parathyroid glands

Learning objectives

To understand:

- The anatomy of the parathyroid glands
- The physiology of calcium regulation
- The underlying causes of hypercalcaemia and appropriate emergency management
- The aetiology, presentation, investigation and management of primary hyperparathyroidism and associated special cases
- The aetiology, presentation, investigation and management of secondary and tertiary hyperparathyroidism
- The aetiology and management of parathyroid carcinoma

INTRODUCTION

The parathyroid glands were first described by Sir Richard Owen in a neck dissection of an Indian rhinoceros at the London Zoological Gardens in 1850. Credit for recognition of the 'glandulae parathyreoidae' goes, however, to Sandström, who published a monograph in 1887 on dissection of the parathyroid glands and their blood supply in animals and human cadavers. Unfortunately, Sandström committed suicide at the age of 37 and it was not until the 1890s that his work was rediscovered by Gley, who associated tetany following thyroid surgery with removal of the parathyroid glands. In 1905, MacCallum found that he could relieve postoperative tetany by the injection of parathyroid extract. While the association between parathyroid enlargement and bone disease was reported in 1907, it was not until 1925 that the first parathyroidectomy was performed by Mandl in Vienna on Albert Gahne, a tram conductor with severe primary hyperparathyroidism (PHPT) and osteitis fibrosa cystica.

ANATOMY OF THE PARATHYROID GLANDS

The developmental embryology and surgical anatomy of the parathyroid glands are intimately linked, and knowledge of both is essential for successful surgical treatment of parathyroid disease.

The parathyroid glands, of which there are four, develop from the third and fourth pharyngeal pouches between the fifth and 12th weeks of gestation. They are typically described as 'Portland brick' (yellow/brown) in colour and weigh approximately 30 mg. Approximately 13% of the population have abnormal parathyroid tissue, with 5% having a true supernumerary gland. The blood supply of both the superior and inferior parathyroid glands arises from the inferior thyroidal artery. While the location of the individual glands may vary significantly, there appears to be a degree of symmetry between opposite sides that can be helpful during surgical dissection.

The inferior parathyroid gland and the thymus arise from the third pharyngeal pouch. As a result of the longer normal embryological descent, there is correspondingly more variation in their anatomical position. However, in more than 50% of cases they are located at the inferior pole of the thyroid gland, on the anterior, lateral or posterior surface. The gland itself is freely mobile within a globule of fat adjacent to the lower pole (***Figure 56.1a***).

The superior parathyroid glands arise from the dorsal portion of the fourth pharyngeal pouch. As a result of their more limited embryological descent they are more constant in position. In more than 80% of patients, the superior parathyroid glands are located at the posterior aspect of the thyroid lobe in an area 2 cm in diameter, centred 1 cm around the junction of the inferior thyroid artery and the recurrent laryngeal nerve in strict proximity to the cricothyroid junction (***Figure 56.1b***). The parathyroid glands are closely associated with, but contained within, a halo of fat that is freely mobile over the thyroid capsule.

Sir Richard Owen, 1804–1892, English comparative anatomist and palaeontologist. First director of the Natural History Museum, London, UK, and Hunterian Professor at the Royal College of Surgeons of England.
Ivar Viktor Sandström, 1852–1889, medical student, Uppsala, Sweden.
Marcel Eugene Gley, 1857–1930, French pathologist.
William J MacCallum, 1874–1944, Professor of Pathology, Johns Hopkins Hospital, Baltimore, MD, USA.
Felix Mandl, 1892–1957, Professor of Surgery, Vienna, Austria.

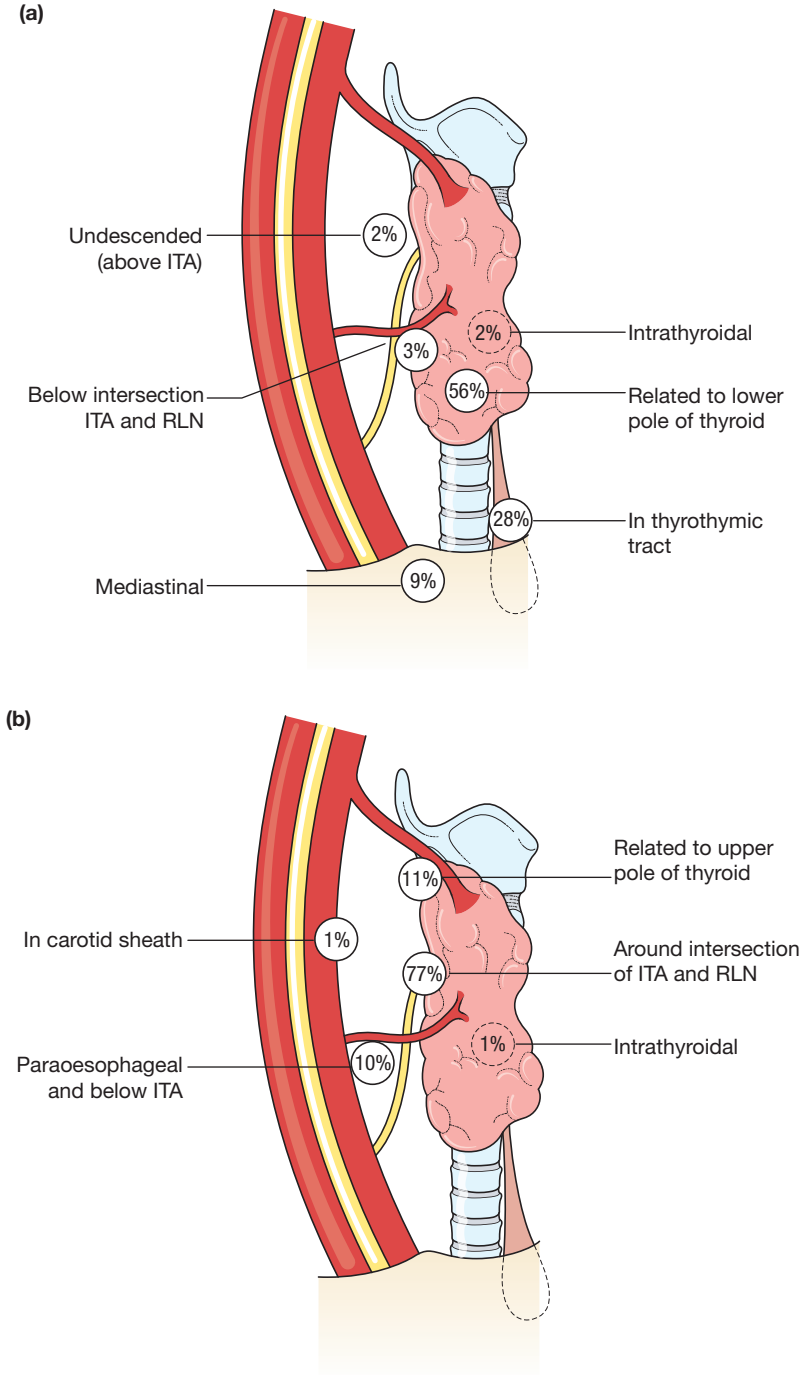

Figure 56.1 Potential locations of the inferior **(a)** and superior **(b)** parathyroid glands. ITA, inferior thyroid artery; RLN, recurrent laryngeal nerve.

CALCIUM AND PARATHYROID HORMONE REGULATION

The parathyroid glands play a central role in the regulation of serum calcium levels through the production of the active 84-amino-acid peptide, parathyroid hormone (PTH). PTH is secreted in response to low serum calcium or high serum magnesium levels. It is initially cleaved in the liver, yielding an inactive C-terminal that is cleared by the kidneys. The N-terminal fragment is responsible for the biological activity of PTH on peripheral tissues. The active circulating molecule has a half-life of approximately 3–5 minutes in patients with normal renal function.

PTH acts directly on the kidneys, bone and the gastrointestinal tract to activate intracellular second messengers, including cyclic AMP and calcium. In the kidneys, PTH increases serum calcium levels by increasing resorption of calcium from the renal tubules and increasing the hydroxylation of 25-hydroxyvitamin D to the biologically active 1,25-dihydroxyvitamin D. Active vitamin D increases both the resorption of phosphorus in the kidneys and the absorption of calcium from the gastrointestinal tract. In bone, PTH acts on

osteoblasts and osteoclasts to increase bone turnover, thereby increasing the amount of calcium in the extracellular space (*Figure 56.2*).

Calcitonin, which is synthesised by the parafollicular C cells of the thyroid gland, acts as the physiological antagonist to PTH. Calcitonin decreases serum calcium by decreasing bone turnover.

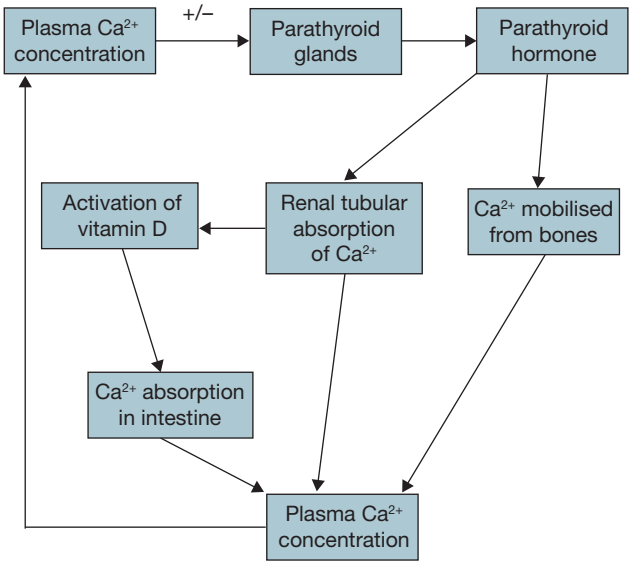

Figure 56.2 The actions of parathyroid hormone.

PRIMARY HYPERPARATHYROIDISM

The early descriptions of patients with PHPT were dominated by those with osteitis fibrosa cystica. Brown tumours of the long bones and associated subperiosteal bone reabsorption, distal tapering of the clavicles and the classical 'salt and pepper' erosions of the skull were typical findings. Over 80% of patients had associated renal stones, significant neuromuscular dysfunction and muscle weakness. This led to the traditional mnemonic that patients with PHPT presented with 'bones, stones, abdominal groans and psychiatric overtones'. The introduction of the automated serum chemical autoanalyser in the 1970s as well as the radioimmune assay to accurately measure circulating PTH levels radically improved early diagnosis of PHPT, such that the majority of patients are now identified incidentally on routine biochemical investigations and are asymptomatic. The current controversies, therefore, centre on the indications for intervention, either surgically or medically.

Presentation

PHPT is defined as hypercalcaemia in the presence of an unsuppressed and therefore relatively, or absolutely, elevated PTH level. Prevalence of the disease is reported to be 0.2–0.5%, with approximately 100 000 new cases per year in the USA. The majority of PHPT is sporadic in nature. Familial disease can occur in multiple endocrine neoplasia (MEN) type 1 or type 2A or as a familial cluster. Patients usually present in the fifth or sixth decades and there is a female predominance with a ratio of 3:1.

Patients are typically identified incidentally with an elevated total calcium or following routine assessment of bone densitometry (DEXA scan). Most patients will, however, have some vague constitutional symptoms, such as fatigue, muscle weakness, depression or some mild memory impairment on questioning. The presence of kidney stones remains the most common clinical manifestation of symptomatic PHPT. Between 15% and 20% of patients will have nephrolithiasis and over 40% of patients will have hypercalciuria. Increasingly, postmenopausal women present with significant osteopenia or osteoporosis in the distal one-third of the radius with a minimal reduction in the lumbar spine, which prompts further investigation. This distribution arises as PTH appears to be catabolic at cortical sites (distal one-third of the radius) and anabolic at cancellous sites (lumbar spine).

PHPT may present with pancreatitis, although it is rarely seen in patients with milder forms of the disease. Common epidemiologically linked disorders, such as hypertension and peptic ulcer disease, are often encountered. Clinical examination is usually normal. Band keratopathy, pathognomonic of the disease and due to deposition of calcium phosphate crystals in the cornea, is now rarely identified.

The differential diagnosis of PHPT includes other causes of hypercalcaemia, which are usually readily distinguishable (*Table 56.1*). It is important to exclude the presence of a widespread malignancy, in which patients will typically have other symptoms. The exception to this rule is multiple myeloma, in which hypercalcaemia can be the presenting

TABLE 56.1 Causes of hypercalcaemia.

Endocrine	• Primary hyperparathyroidism • Thyrotoxicosis • Phaeochromocytoma
Renal failure	• Secondary hyperparathyroidism • Tertiary hyperparathyroidism
Malignant disease	• Skeletal metastatic disease • Multiple myeloma, lymphoma, leukaemia • Solid tumours (PTH-related peptide mediated): lung, renal, squamous cell carcinoma of the head and neck, oesophagus, genital tract
Nutritional	• Excessive vitamin D ingestion • Vitamin A intoxication • Milk-alkali syndrome • Aluminium intoxication
Granulomatous	• Sarcoidosis • Tuberculosis
Inherited disease	• Hypercalciuric hypercalcaemia
Immobilisation	
Paget's disease	
Drug related	• Lithium

PTH, parathyroid hormone.

Sir James Paget, 1814–1899, surgical pathologist, Royal College of Surgeons of England.

complaint. Improvements in the immunoradiometric and immunochemiluminometric assays for PTH can help to distinguish these conditions, as in malignancy PTH levels are typically suppressed.

Hypercalcaemic crisis: presentation and management

Hypercalcaemia is documented in 0.5% of the general population and in up to 5% of hospitalised patients. The vast majority are asymptomatic with a mild to moderate elevation of serum calcium (<3 mmol/L and 3–3.5 mmol/L, respectively) and respond to treatment of the underlying aetiology with associated dietary modification. A small proportion of patients will present symptomatically with a total calcium of >3.5 mmol/L. This is referred to as a hypercalcaemic crisis and requires aggressive medical management.

Although symptoms can be varied, the typical presentation is of acute confusion, abdominal pain, vomiting, dehydration and anuria. Prolongation of the PR interval with a shortened QT interval can be identified on an electrocardiogram (ECG) prior to potentially lethal cardiac arrhythmias. Where the calcium is >4.5 mmol/L, coma and cardiac arrest can occur.

Treatment revolves around increasing renal excretion of calcium, reducing skeletal release of calcium and treatment of the underlying cause. Aggressive rehydration plays a pivotal role. Typically, 200–500 mL/h of normal saline is given to maintain a urine output >100 mL/h, with the caveat that this may be modified to account for associated patient comorbidities. Once intravascular volume has been adequately restored, loop diuretics, such as furosemide, can be used to enhance the renal excretion of calcium. The majority of patients will have normalisation of their calcium with these simple measures.

In patients with advanced malignancy and a serum calcium level >3 mmol/L, agents that blunt the release of calcium from skeletal stores may be required. First-line treatment includes administration of bisphosphonates. These are pyrophosphate analogues that inhibit osteoclast activity in areas of high bone turnover. In the acute setting, these are given intravenously owing to poor absorption in the gastrointestinal tract. Calcitonin can be used to both decrease osteoclastic activity and increase renal excretion of calcium. It has a short duration of action and is usually used as a bridge to reduce calcium until the sustained action of the bisphosphonates is seen. Finally, glucocorticoids (prednisolone) can be used to enhance the action of calcitonin. They increase calciuresis and decrease intestinal absorption of calcium. As a result, they may also play a role in diseases associated with vitamin D excess.

Pathology

The underlying aetiology of PHPT is usually a solitary parathyroid adenoma; however, in a small number of patients (2–4%) there are double adenomas. It may occur in a sporadic fashion or it can be familial (approximately 10%) (MEN type 1, type 4, type 2A or hyperparathyroidism–jaw tumour syndrome [HPT-JT]) in nature.

The only known risk factor for the development of PHPT is a history of prior neck irradiation. The underlying genetic pathogenesis of PHPT remains unclear. However, genes regulating the cell cycle, such as *MEN1* and *CCND1*, have been recognised as playing an important role owing to the clonal nature of adenomas. Somatic mutations in *MEN1*, which encodes menin, occur in 12–35% of sporadic cases and rearrangements or overexpression of *CCND1*, which encodes cyclin D1, have been demonstrated in 20–40% of patients. Upregulation of cyclin D may lead to a clonal proliferation within the parathyroid glands. This does not alter the set point of calcium but the hyperplasic nature of the parathyroid cells themselves causes excessive secretion of PTH.

Multigland disease is less common, occurring in approximately 15% of patients. No clinical features differentiate single from multigland disease, although multigland disease is more commonly associated with familial syndromes such as MEN types 1 and 2A, as well as the chronic ingestion of lithium.

Diagnosis

PHPT is a biochemical diagnosis. Only when the disease has been confirmed biochemically should localisation studies be undertaken. Positive imaging does not confirm the diagnosis and negative findings cannot rule it out.

PHPT is defined as an elevated total, or more specifically ionised, calcium in the presence of an inappropriately elevated or unsuppressed PTH. It is associated with a low serum phosphate in the setting of normal creatinine and vitamin D levels; 24-hour urinary excretion of calcium may be normal or elevated. It is important to perform a 24-hour urinary collection to rule out the presence of the rare familial hypocalciuric hypercalcaemia (FHH). Alkaline phosphatase may be elevated in patients in whom there is concomitant bone disease. This is important to recognise preoperatively as the surgeon should anticipate significant postoperative hypocalcaemia due to the development of hungry bone syndrome.

Localisation studies

> In my opinion, the only localising study required in a patient with untreated primary hyperparathyroidism is to localise an experienced parathyroid surgeon.
>
> John Doppman, 1986

Historically, preoperative localisation studies for PHPT were considered less important than identifying an experienced surgeon. However, with a shift away from the traditional four-gland (cervical neck) exploration to more minimally invasive procedures, accurate preoperative identification is critically important to guide surgical strategy.

There are a variety of both non-invasive and invasive studies commonly in use. Non-invasive radiology includes nuclear medicine-based studies, ultrasonography and four-dimensional (4D) computed tomography (CT) scanning. Invasive imaging is largely reserved for reoperative surgery and includes ultrasound or CT-guided fine-needle aspiration with

John L Doppman, 1928–2000, radiologist, National Institutes of Health, USA, developed the technique of selective venous sampling for parathyroid localisation.

concomitant PTH assays, parathyroid angiography or selective venous sampling for the PTH gradient.

Nuclear medicine-based studies (sestamibi scanning)

The use of sestamibi (2-methoxy-2-methylpropylisonitrile [MIBI]) for parathyroid localisation was first described in 1989 and is now regarded as the most accurate and reliable method for imaging the parathyroid glands. It is safe and reproducible and, while it has a sensitivity and specificity similar to ultrasonography, it may image glands in ectopic positions better (*Figure 56.3a*).

Sestamibi accumulates in mitochondria and therefore washes out at differential rates depending on the number of mitochondria within individual tissues. Parathyroid adenomas often have a high concentration of oxyphilic cells with high mitochondrial content. These retain tracer, and adenomas are therefore associated with a slow washout when compared with the thyroid gland. There are three different protocols for sestamibi scanning: single-isotope dual-phase scan, dual-isotope subtraction imaging and single-photon emission computed tomography (SPECT). The sensitivity and specificity of sestamibi, regardless of the protocol used, are 79% and 90%, respectively. False positives are rare but may arise from some solid thyroid nodules, such as Hürthle cell nodules, that are associated with high oxyphilic content. These can be reduced by the addition of a thyroid-specific radioactive tracer, such as ^{99}Tc-pertechnetate and subsequent subtraction images.

Ultrasonography

Ultrasonography is a non-invasive, inexpensive method of imaging the parathyroid glands (*Figure 56.3b*). Parathyroid adenomas are typically oval or elongated, bi- or multilobed hypoechoic structures. Rarely, adenomas may be cystic or heterogeneous in nature. Giant adenomas are described as those over 3 cm in size. Ultrasonography is not associated with any radiation exposure and has the advantage of being able to identify and facilitate biopsy of any concomitant thyroid pathology. However, ultrasonography is operator, lesion size and location dependent. Critically, ultrasonography may

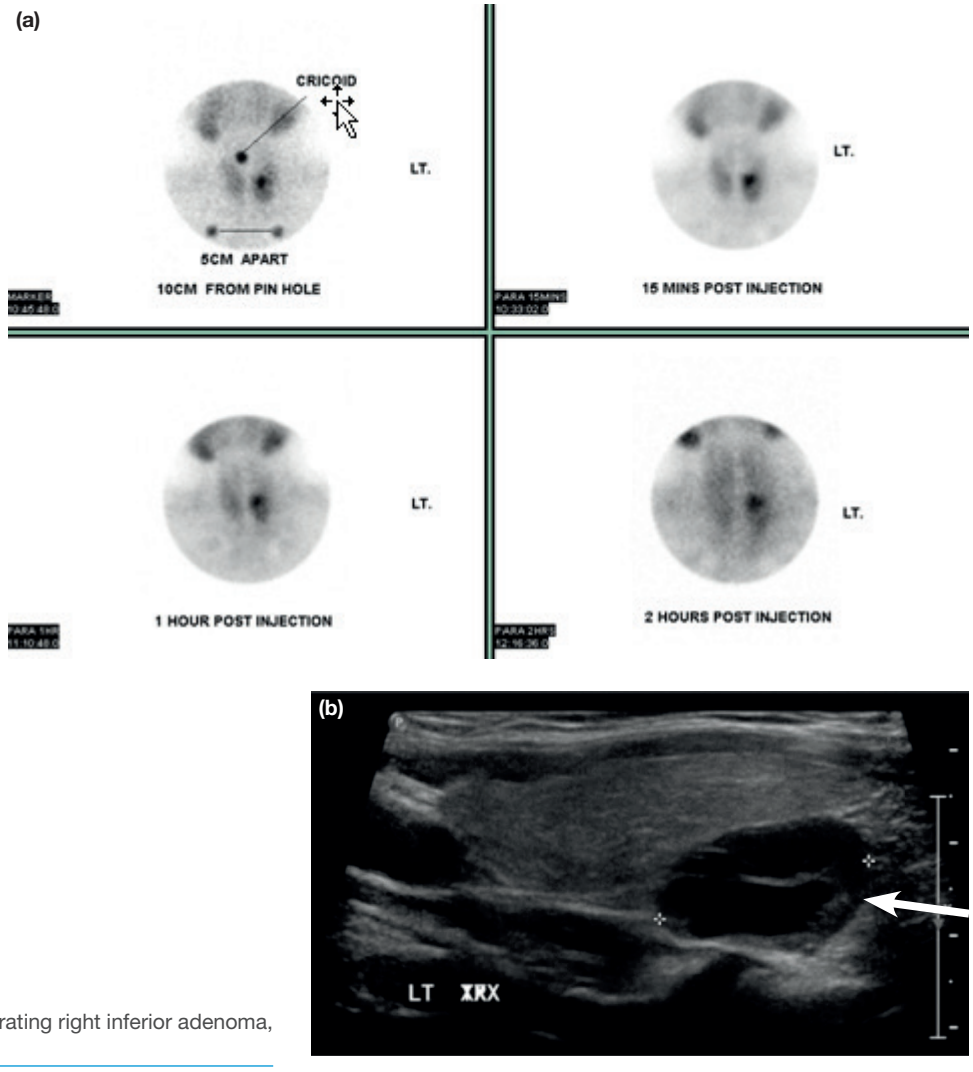

Figure 56.3 Sestamibi scan **(a)** demonstrating right inferior adenoma, with concordant ultrasonography **(b)**.

Karl Hürthle, 1866–1945, histopathologist, Breslau, Germany (now Wrocław, Poland).

miss adenomas located in retro-oesophageal, retrosternal or retrotracheal areas. It can also be difficult to differentiate between a small parathyroid gland and a normal-appearing lymph node. A meta-analysis of preoperative localisation techniques in PHPT demonstrated that ultrasonography and sestamibi-SPECT have comparable accuracy, with pooled sensitivities of 76.1% and 78.9%, respectively, and positive predictive values (PPVs) of 93.2% and 90.7%, respectively (Krakauer *et al.*, 2016).

Four-dimensional computed tomography scanning/positron emission tomography-computed tomography

Multiphase CT imaging (4D-CT) has become widely utilised to localise disease (***Figure 56.4***). It gives both anatomical and functional information about the parathyroid glands. Using precontrast, postcontrast and delayed images, it demonstrates not only detailed anatomical localisation but, combined with rapid uptake and washout, allows hyperfunctioning glands to be differentiated from lymph nodes that demonstrate a progressive enhancement pattern. The potential disadvantage of 4D-CT scanning is the higher radiation dose when compared with traditional imaging modalities. Modification of the protocol now allows fewer phases to be obtained without compromising outcomes. The initial study in 2006 reported a sensitivity of 88% for lateralisation and 70% for localisation of parathyroid adenomas (Rodgers *et al.*, 2006). A more recent meta-analysis, although limited by the small number of studies, demonstrated a sensitivity and PPV of 89.4% and 93.5%, respectively, when 4D-CT was used as the primary imaging modality. This was reduced to 71.8% and 74.9%, respectively, in cases of negative or inconclusive prior imaging (Cheung *et al.*, 2012).

Positron emission tomography (PET) scanning remains expensive and is not widely available. However, recent data suggest that there may be an incremental value to ^{18}F-fluorocholine PET with the addition of CT scanning for localisation of ectopic adenomas.

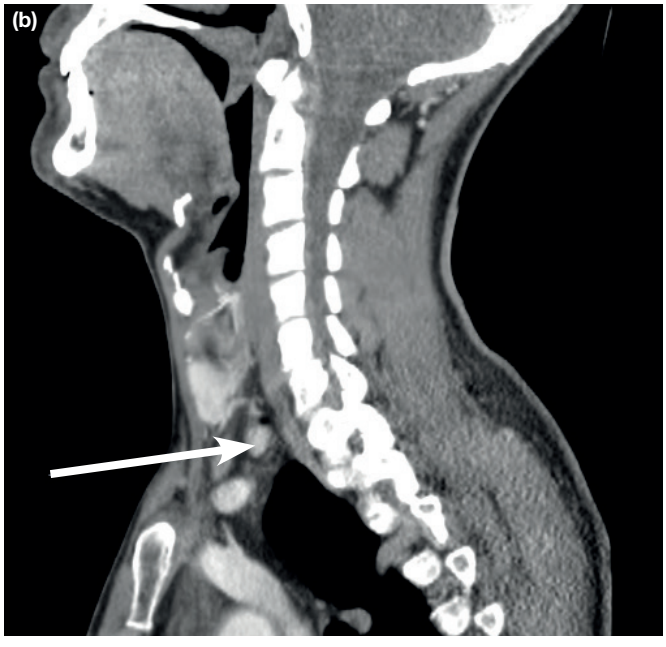

Figure 56.4 (a, b) Four-dimensional computed tomography scanning demonstrating a right inferior parathyroid adenoma (arrows).

Magnetic resonance imaging

Magnetic resonance imaging (MRI) is not commonly used to image the parathyroid glands. However, on T2-weighted images, enlarged parathyroid glands demonstrate significantly increased intensity. In reoperative cases or where the adenoma is located in the mediastinum, MRI may be beneficial, with higher reported sensitivities (50–88%). While the sensitivity of MRI is slightly better than that for CT (64–88%) in primary disease, it has significant limitations. It is expensive, patients can be poorly compliant owing to claustrophobia and the resolution for normal glands or adenomas <5 mm is poor. Similarly, it can be difficult to localise superior glands because of their posterior location, which allows them to be obscured by the thyroid gland.

Parathyroid angiography and venous sampling for parathyroid hormone

Parathyroid angiography is reserved for reoperative cases and is now rarely required owing to improvements in non-invasive imaging modalities. It involves examination of both thyrocervical trunks, both internal mammary arteries and both carotids, with occasional selective superior thyroid artery catheterisation. Vascular parathyroid adenomas appear as a persistent oval or round 'stain' on angiography. Serious complications such as contrast-induced renal failure, embolisation and neurological damage have limited its utility.

Selective venous sampling for PTH can allow accurate localisation of adenomas but an experienced interventional radiologist is vital for success. The venous drainage of the lesion is established when there is a twofold drop in the PTH between the sampled blood and the serum PTH. The sensitivity is reported to be 80% and is equally effective in localising cervical and mediastinal adenomas. However, the false-positive rate of between 6% and 18% limits its utility to reoperative cases.

Management strategies

Surgical management

The mainstay of treatment for PHPT is surgery, addressing the underlying aetiology and allowing not only resolution of biochemical abnormalities but also sustained improvements in end-organ damage. Traditionally a bilateral cervical exploration was performed with reported cure rates of 95–98%. With improvements in preoperative radiological localisation, a more minimally invasive approach has been developed and widely adopted (*Figure 56.5*).

All symptomatic patients should be offered surgery. An expert panel published recommendations on which asymptomatic patients should be considered for surgical intervention (*Table 56.2*). Guidelines from the American Association of Endocrine Surgeons have more liberal indications for surgery. These included patients with cognitive or psychiatric symptoms attributable to PHPT, cardiovascular disease (excluding hypertension) and more non-specific symptoms, such as muscle weakness, impaired functional capacity and abnormal sleep patterns. When criteria have been met and where a single adenoma has been confidently identified by radiological means, a minimally invasive parathyroidectomy may be offered. Conversely, where there is discordant imaging or where imaging fails to identify any parathyroid abnormalities, then a bilateral neck exploration and a three-and-a-half-gland parathyroidectomy or a four-gland parathyroidectomy and autotransplantation should be performed.

Consent for a parathyroidectomy must include the possibility of recurrent laryngeal nerve damage (risk <1%), permanent hypoparathyroidism (requiring lifelong calcium and vitamin D supplementation; risk 0.5%) and persistent (5%) or recurrent hyperparathyroidism. Persistent disease is defined as an elevated serum calcium within 6 weeks of surgical intervention and recurrent disease is defined as an increase in calcium levels after 6 months but with an intervening period of normocalcaemia.

TABLE 56.2 Consensus guidelines for surgical intervention in asymptomatic primary hyperparathyroidism.

Measurement of serum calcium	0.25 mmol/L (1.0 mg/dL) above the upper limit of normal
Skeletal	• BMD by DEXA; T score –2.5 at lumbar spine, total hip, femoral neck or distal one-third of radius • Vertebral fracture
Renal	• Creatinine clearance <60 mL/min • 24-hour urinary calcium >10 mmol/dL (>400 mL/day) or increased risk of stone formation by risk analysis
Age	<50 years

BMD, bone mineral density; DEXA, bone densitometry.
Adapted from Bilezikian *et al*. (2014).

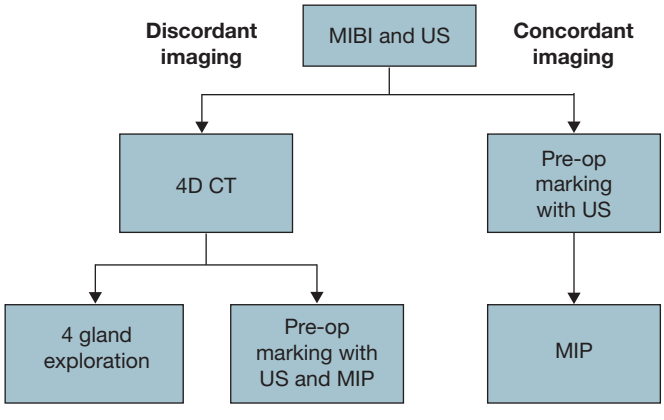

Figure 56.5 Localisation paradigm and management strategies. 4D CT, four-dimensional computed tomography; MIBI, 2-methoxy-2-methylpropylisonitrile; MIP, minimally invasive parathyroidectomy; US, ultrasonography.

Minimally invasive (focused) parathyroidectomy

Minimally invasive approaches are based on the principle that over 80% of individuals with PHPT have a single adenoma. Although there is no strict definition of the procedure, it commonly refers to the removal of a localised abnormal parathyroid gland through an incision less than 3 cm in length (*Figure 56.6*). The term encompasses open approaches (central and lateral incisions) and video-assisted and radio-guided parathyroidectomies. A number of randomised studies have shown that the focused approach has similar cure rates to

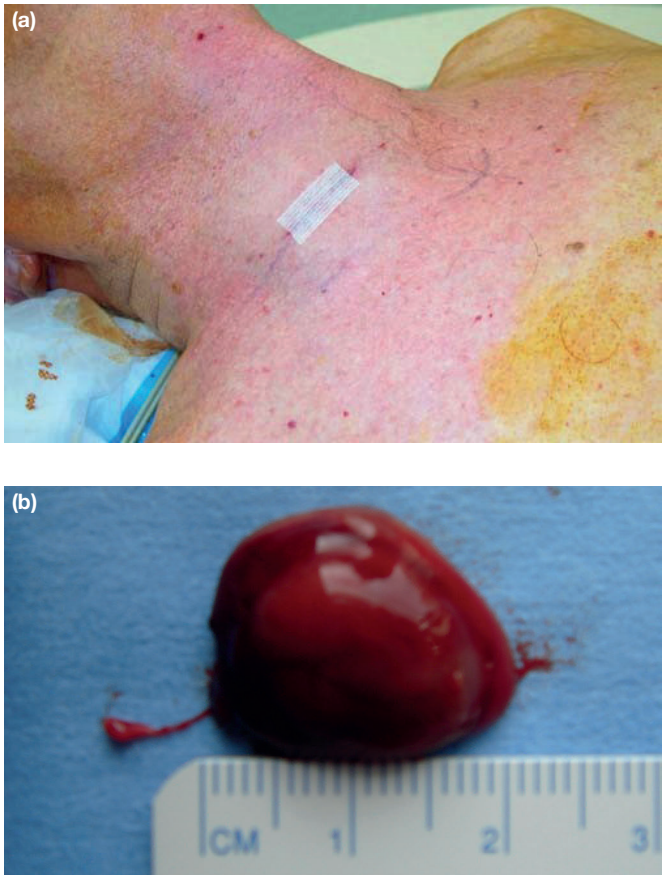

Figure 56.6 (a) Minimally invasive parathyroidectomy through a lateral approach; **(b)** the excised parathyroid adenoma.

a cervical exploration but with reduced rates of postoperative hypocalcaemia, shorter operating times, potentially less pain and better cosmesis.

The need to convert from a focused to a cervical exploration may be guided by the use of intraoperative PTH measurements. Routine use is, however, controversial owing to high false-positive and false-negative rates. The basic concept is that the half-life of circulating PTH is 3–5 minutes and there should therefore be a significant drop detected in the plasma PTH following resection of a single adenoma. If no such drop is detected, then multigland disease may be suspected and conversion to a bilateral neck exploration should be considered. The Miami criteria were developed to determine the extent of resection. A drop in the PTH into the normal range and to less than half the maximum preoperative PTH at 10 minutes appears to accurately predict single-gland disease (***Figure 56.7***).

Bilateral neck exploration

A traditional cervical neck exploration is required where imaging is negative or discordant, in MEN (type 1 or type 2A) or in lithium-induced PHPT. A transverse collar (Kocher's) incision is made and the subplatysmal plane developed. The deep cervical fascia is divided between the strap muscles and these are retracted. The thyroid lobes are mobilised and the middle thyroid vein may be divided when present.

Identification of the recurrent laryngeal nerve and the middle thyroid artery allows a starting point for a systematic exploration (see ***Chapter 55***). All four glands are identified. Three and a half glands are resected, with half of a vascularised parathyroid left *in situ*. The other half of the gland should be sent for frozen section to confirm the presence of parathyroid tissue (***Figure 56.8***). Ideally the most normal-appearing parathyroid is left *in situ*. With this caveat in mind, where possible an inferior gland should be left. It is marked with a non-absorbable suture to aid identification in the presence of recurrent disease, where resection can be achieved without increasing the risk of damage to the recurrent laryngeal nerve. Alternatively, all four glands can be resected and a forearm autotransplant created. Small pieces of parathyroid are sutured into pockets created in the brachioradialis muscle. Cure rates and rates of persistent and recurrent disease appear to be similar, regardless of the type of procedure used. However, in recurrent disease it can be difficult to identify the location of the recurrent tissue when an autotransplant is performed.

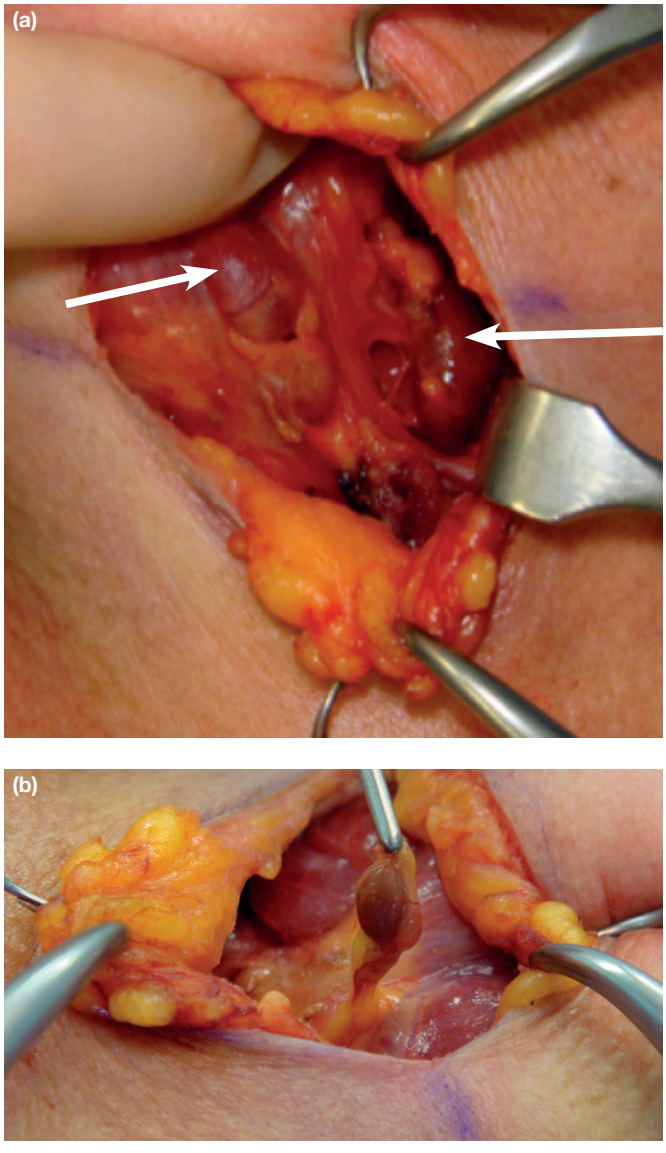

Figure 56.8 Parathyroidectomy with exposure of the left superior and inferior parathyroid glands (white arrows) *in situ* **(a)** and left superior gland mobilised on its vascular pedicle **(b)**.

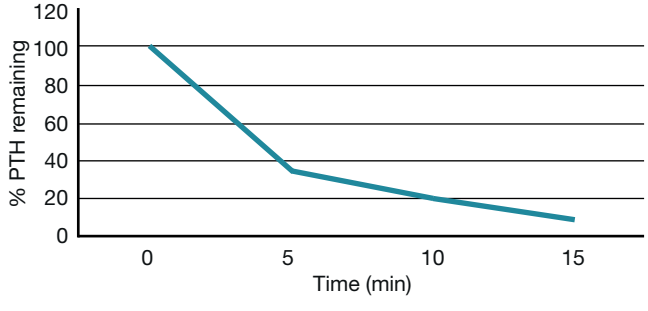

Figure 56.7 Miami criteria for intraoperative parathyroid hormone (PTH) measurement. Drop of PTH into the normal range and less than half the maximum value at 10 minutes postresection.

Thymectomy and resection of mediastinal adenomas

The incidence of clinically significant supernumerary glands is increased in patients with multigland disease or those with hereditary syndromes. A thymectomy should be routinely undertaken for patients with *MEN1*-associated PHPT or in secondary hyperparathyroidism. A cervical thymectomy is performed by dissecting close to the thymic capsule, exploring the cervical part of the gland. The mediastinal part of the gland can be removed by gentle upwards traction, with ligation of the veins draining into the innominate vein. The end of the

Emil Theodor Kocher, 1841–1917, surgeon, Berne, Switzerland, awarded the Nobel Prize in Physiology or Medicine in 1909 for his research on the thyroid.

gland is tapered and rarely requires formal ligation. A median sternotomy is not required where a prophylactic thymectomy is being performed.

Mediastinal adenomas are rare, accounting for less than 1% of all parathyroid adenomas. They will be typically identified on preoperative imaging. Resection can be achieved either by an open sternotomy or increasingly by a thoracoscopic approach. A minimally invasive approach can be particularly effective where the abnormal gland lies immediately deep to the mediastinal pleura. It can confer significant advantages in length of hospital stay and complication rates.

Permanent hypoparathyroidism

Permanent hypoparathyroidism is defined as the continuing need for calcium and/or vitamin D replacement at 1 year postoperatively. It is a rare complication when surgery is undertaken for PHPT (0.5%), but in secondary hyperparathyroidism it can range from 4% to 12%. Symptoms and signs relate to serum calcium levels. Symptoms include mild circumoral or digital numbness and paraesthesia, carpopedal or laryngeal spasms and cardiac arrhythmias. Chvostek's and Trousseau's signs may be elicited. Chvostek's sign refers to contraction of the ipsilateral facial muscles on percussion of the facial nerve below the zygoma. Trousseau's sign refers to the development of carpopedal spasm secondary to occlusion of the arm (usually with a blood pressure cuff).

Biochemical investigations include total and ionised calcium levels as well as serum magnesium levels. An ECG may demonstrate a prolonged QT interval or QRS complex changes. Mild hypocalcaemia can be treated with oral calcium and vitamin D supplementation. Acute symptomatic hypocalcaemia is an emergency and should be corrected with intravenous as well as oral calcium and vitamin D replacement. Traditionally, 10 mL of 10% calcium gluconate is administered slowly intravenously. Supplemental magnesium may also be required, owing to the synergistic action of transporters for calcium and magnesium.

Medical management

Medical management is warranted in patients who are deemed unfit or who have contraindications to surgical intervention, in patients with failed surgical intervention or in the long-term management of parathyroid carcinoma. The aims are to prevent skeletal complications (improve bone mineral density and reduce fracture risk) and to stabilise biochemical parameters. There are only limited data on the long-term efficacy of such an approach as surgery is known to provide durable responses.

Bisphosphonates/denosumab

Bisphosphonates are pyrophosphate analogues that are concentrated in areas of high bone turnover. They inhibit osteoclast activity and apoptosis, thereby increasing bone mineralisation and reducing bone turnover. Studies looking at the management of PHTP utilising bisphosphonates are limited by small numbers and short follow-up. However, use does appear to stabilise bone mineral density without markedly altering the underlying serum biochemistry. Denosumab is a monoclonal antibody that works as a receptor activator of nuclear factor- κB (RANK) ligand inhibitor. Data from the DENOCINA trial suggest that it may be a valid treatment option for patients in whom surgery is undesirable.

Hormone replacement therapy and selective oestrogen receptor antagonists

Hormone replacement therapy (HRT) has been shown to improve bone mineral density and reduce the associated fracture risk in postmenopausal women by reducing bone turnover. Two non-randomised controlled trials have shown a durable and similar response to surgery for PHTP at 4 years, with improvements in bone mineral density but without any improvement in the underlying serum biochemistry. The rationale for the use of selective oestrogen receptor antagonists (SERMs) is that they should confer the benefits of HRT but without the potential adverse vascular and breast effects. The effect on the bone mineral, however, appears to be less significant than that of HRT.

Calcimimetics

The extracellular calcium-sensing receptor on the parathyroid cell surface negatively regulates secretion of PTH. Activation of the receptor decreases secretion of PTH, thereby decreasing bone turnover. Calcimimetics, such as cinacalcet, amplify the sensitivity of the calcium-sensing receptor to extracellular calcium, altering the set point and thereby decreasing PTH production. Cinacalcet was approved for use in PHPT by the European Medicines Agency in 2008 and subsequently by the US Food and Drug Administration in 2011 for the treatment of severe hypercalcaemia in patients with PHPT who were unfit for parathyroidectomy. Normalisation of serum calcium levels can be achieved with a similar reduction in the level of PTH, although not to within the normal range. Despite this, neither the urinary calcium nor the bone mineral density appear to change even after 3 years of treatment. Drug tolerance, especially gastrointestinal side effects, can be problematic and may limit the duration of usage.

SPECIAL CASES

Lithium-induced hyperparathyroidism

Lithium-induced hyperparathyroidism occurs in 10–15% of patients treated with long-term lithium. It is generally associated with a mild elevation in calcium with failure to suppress PTH. The underlying aetiology can be either gland hyperplasia, with lithium originally thought to stimulate all parathyroid tissue, or a single adenoma, which has been shown to occur in 33–49% of cases. It has recently been suggested that the hyperparathyroidism may be caused by interference with the parathyroid kinase C signal transduction system and the Wnt pathway. Biochemical abnormalities may resolve with discontinuation

Frantisek Chvostek, 1835–1884, physician, The Jasefsacademie, Vienna, Austria.
Armand Trousseau, 1801–1867, physician, Hôtel Dieu, Paris, France.

of lithium. Surgery is indicated where ongoing treatment with lithium is required or where abnormalities persist following withdrawal of lithium. Minimally invasive surgery is relatively contraindicated in these patients because of the high incidence of multigland disease. Excision, however, should be limited to those glands that are obviously enlarged at exploration rather than a formal three-and-a-half-gland excision.

Familial syndromes

Familial hyperparathyroidism can be part of a well-recognised endocrine disorder, but it may also occur in isolation in a non-syndromic form. PHPT occurs as a central facet in multiple MEN type 1, type 4, type 2A, HPT-JT, autosomal dominant mild hyperparathyroidism and FHH.

Familial isolated hyperparathyroidism

Familial isolated hyperparathyroidism occurs when patients have PHPT without any other associated endocrinopathies. The underlying genetic abnormality has yet to be fully elucidated, but the syndrome has been linked to known mutations in the *MEN1* gene, the *HRPT2* gene as well as the calcium-sensing receptor gene. A significant proportion of patients will belong to the MEN 1 family, with documented recognised mutations but without expression of other endocrinopathies. Hyperparathyroidism should be treated with a formal bilateral neck exploration and management as per patients with MEN.

MEN type 1-associated hyperparathyroidism

MEN type 1 is a rare autosomal dominant syndrome consisting of tumours of the parathyroids, endocrine pancreas–duodenum and the pituitary (the three Ps). It occurs in approximately 1 per 30 000 individuals. It can also be associated with adrenal adenomas or carcinoma, foregut carcinoids and lipomas. Mutations, of which there are over 1000 identified in different families, occur in the *MEN1* gene, which encodes the protein menin. Menin acts as a tumour suppressor. Patients typically present with young onset (20–30 years of age) of symptomatic hyperparathyroidism and over 95% of patients will have PHPT before the age of 40 years.

Surgical intervention in MEN type 1 aims to obtain and maintain normocalcaemia for the longest time possible. In general, it is associated with the presence of multigland parathyroid disease and as such has mandated a bilateral cervical exploration with at least a subtotal parathyroidectomy and cervical thymectomy. A subtotal parathyroidectomy removes three and a half glands with half of the most normal-appearing parathyroid left *in situ* with a marking stitch to facilitate reoperative intervention. A total parathyroidectomy and forearm autotransplantation is an acceptable alternative. Detailed intraoperative notes, including diagrams, should be kept. Despite meticulous and extensive surgery, the rates of both persistent and recurrent disease remain high in this group of patients (up to 62%) regardless of the type of surgery performed. Unfortunately, the rates of postoperative permanent hypocalcaemia are also high, with published rates up to 47%.

MEN type 4-associated hyperparathyroidism

MEN type 4 is an autosomal dominant syndrome that comprises the same combination of tumours as MEN type 1 but is a rarer cause of hereditary PHPT. It arises as a result of an inactivating pathogenic variant in the cyclin-dependent kinase inhibitor *CDKN1B* gene. It should be managed in the same fashion as MEN type 1.

MEN type 2A-associated hyperparathyroidism

MEN type 2A consists of medullary thyroid carcinoma (MTC), unilateral or bilateral phaeochromocytomas and PHPT. PHPT occurs in approximately 20% of patients and is associated with mutations in codon 634 in the RET proto-oncogene. The majority of patients will be asymptomatic, with a mild elevation in calcium and asymmetrically enlarged parathyroid glands. It is extremely important that the presence of a phaeochromocytoma is excluded prior to surgical intervention. Surgery is usually performed for MTC, with the parathyroid enlargement often being a coincidental intraoperative finding (see ***Chapter 55***). In this setting, with extensive surgery for MTC, the primary aim of treatment is to avoid hypoparathyroidism. A conservative stance is adopted with resection of grossly enlarged glands, but with preservation of parathyroid tissue where possible and identification with a marking stitch in the neck.

Hyperparathyroidism–jaw tumour syndrome

HPT-JT is a rare cause of PHPT. It arises as a result of inactivating mutations in the *HRPT2/CDC73* gene on chromosome 1q21–q31, encoding parafibromin. It classically presents with early-onset PHPT (mean age of 32 years), the aetiology of which can be either single- or multigland disease but is predominantly cystic in nature. It presents with severe hypercalcaemia and is associated with an increased risk of an underlying parathyroid carcinoma. Approximately 40% of patients will have the pathognomonic ossifying jaw fibromas of the maxilla or mandible. Other associated abnormalities include renal pathology (hamartomas, polycystic kidney disease and adult Wilms' tumours) and female patients may have uterine malignancies. Surgical intervention involves removal of all enlarged parathyroid glands.

Where there is concern for a parathyroid carcinoma, great care must be taken to avoid tumour spillage. Whether or not an en bloc resection of the enlarged suspicious parathyroid and the adjacent thyroid lobectomy is required remains controversial.

Autosomal dominant mild hyperparathyroidism

This is a rare autosomal dominant syndrome presenting with hypercalcaemia and hypercalciuria. It is associated with a mutation in the calcium-sensing receptor gene. It typically presents in patients who are over 40 years of age and all patients have PHPT. Surgical intervention requires a bilateral neck exploration as it is associated with multigland disease.

Max Wilms, 1867–1918, Professor of Surgery, University of Heidelberg, Germany.

Familial hypocalciuric hypercalcaemia

FHH is not a surgical disease and therefore preoperative diagnosis is imperative for the surgeon. FHH arises as a result of heterozygous mutations in the calcium-sensing receptor gene on chromosome 3. Benign FHH typically presents with mild hypercalcaemia in young (<10 years of age) asymptomatic patients. Patients with FHH have a normal or slightly elevated PTH level, increased serum magnesium levels and hypocalciuria. A low urinary calcium–creatinine clearance ratio is used to discriminate between FHH and mild PHPT. Patients rarely require intervention and surgical intervention is not indicated.

Criteria for genetic testing

In clinical practice, specific criteria can be employed to determine which patients are at the highest risk of hereditary PHPT. The current NHS England National Genomic Test Directory testing criteria from March 2019 for familial hyperparathyroidism state that testing should be considered for patients with PHPT and a creatinine clearance ratio >0.02 who meet **one** of the following criteria:

1. presenting before the age of 35 years **or**
2. presenting before the age of 45 years with **one** of:
   - **a** proven multigland involvement **or**
   - **b** hyperplasia on histology **or**
   - **c** ossifying fibroma(s) of the maxilla or mandible **or**
   - **d** at least one first-degree relative with unexplained hyperparathyroidism.

The testing criterion for FHH is a creatinine clearance ratio <0.02.

Summary box 56.1

Primary hyperparathyroidism

- Presentation is now typically asymptomatic rather than the classical 'bones, stones, abdominal groans and psychiatric overtones'
- The diagnosis of PHPT is a biochemical one
- Presence of an elevated ionised calcium with an inappropriately elevated/not suppressed PTH level confirms the diagnosis
- Sestamibi and focused neck ultrasonography are the first-line radiological investigations
- 85% of cases are due to a single adenoma
- Minimally invasive parathyroidectomy is a safe and acceptable alternative to a four-gland exploration in the presence of localised disease
- Familial syndromes and disease that is not localised require a formal four-gland exploration and three-and-a-half-gland parathyroidectomy

SECONDARY HYPERPARATHYROIDISM

Secondary hyperparathyroidism is defined as a derangement in calcium homeostasis, which leads to a compensatory increase in PTH secretion. It occurs primarily as a result of chronic kidney disease and is therefore sometimes referred to as renal hyperparathyroidism. Other underlying causes include gastrointestinal malabsorption, vitamin D deficiency, liver disease or chronic lithium usage.

The pathogenesis of secondary hyperparathyroidism is related to renal dysfunction. Abnormalities in the renal tubular absorption of phosphate lead to hyperphosphataemia. This acts directly on the parathyroid cells and stimulates PTH secretion. More recent translational research has identified a novel phosphaturia hormone, fibroblast growth factor 23 (FGF23). This is progressively secreted from osteocytes to compensate for chronic phosphate retention that in turn leads to a reduction in 1,25-dihydroxyvitamin D, which by reducing the intestinal absorption of calcium also acts to increase secretion of PTH. Previous studies in patients with chronic renal disease have shown that there is a reduction in the expression of the vitamin D receptor and the calcium-sensing receptor, with associated skeletal resistance to PTH. These factors interact to form the complex pattern leading to progressive secondary hyperparathyroidism in the setting of chronic renal disease.

The pathological characteristics associated with secondary hyperparathyroidism include hyperplasia, asymmetrical glandular enlargement or nodularity. This differentiation is important as, when the parathyroid gland becomes nodular, it loses expression of the vitamin D receptor and the calcium-sensing receptor gene. It has been proposed that nodular parathyroid glands may be resistant to calcimimetics and therefore refractory to medical management.

Diagnosis

The classical symptoms associated with secondary hyperparathyroidism are seen less commonly now, with greater awareness of the disease and the resultant earlier medical intervention. However, progressive bone disease, especially bone pain, can occur with associated soft-tissue calcium deposits (***Figure 56.9***).

The diagnosis of secondary hyperparathyroidism is characterised by hypocalcaemia or normocalcaemia with an elevated PTH. Patients have a high serum phosphate and a low vitamin D. Traditional plain radiographs now rarely demonstrate the pathognomonic osteitis fibrosa cystica. However, bone densitometry (DEXA scan) typically demonstrates osteopenia or osteoporosis.

The diagnosis of secondary hyperparathyroidism is a biochemical one. In general, localisation studies are not undertaken as minimally invasive surgery is not indicated. However, neck ultrasonography can be performed to identify patients with nodular hyperplasia who may be refractory to medical management. Localisation studies are helpful in patients with recurrent disease in order to identify ectopic parathyroid tissue, especially in the mediastinum. In cases of recurrent disease, when there is no evidence of active disease in the neck and a previous allograft has been used to the forearm, selective venous sampling for PTH in the neck and the brachial vein on the side of the graft can be useful. This is known as the Casanova test and to prove that the recurrent disease is located in the grafted arm (graft hyperplasia) the ratio must be greater than 20:1.

Daniel Casanova, contemporary, University of Cantabria, Santander, Spain.

Figure 56.9 Secondary hyperparathyroidism. Radiograph showing ectopic calcification.

Calciphylaxis

Calciphylaxis (calcific uraemic arteriolopathy) is a syndrome of disseminated calcification resulting in both vascular calcification and skin necrosis. It accounts for approximately 4% of patients undergoing surgical intervention for secondary hyperparathyroidism. It presents with expanding painful cutaneous purpuric lesions, predominantly on the extremities, although they can also be seen on the lower abdomen. The underlying tissue calcification within the arteriolar and small vascular walls leads to ischaemic necrosis and the development of gangrene, which in turn leads to overwhelming sepsis and death. The majority of these patients will have an elevated calcium × phosphate product but it is not usually associated with an extremely high PTH level. The underlying aetiology remains unclear but a number of potential factors have been postulated. A reduction in the serum levels of a calcification inhibitory protein, α_2-Heremans–Schmid glycoprotein, and abnormalities in smooth muscle cell biology in uraemic patients may play a role in the development of the syndrome. Prognosis for these patients is extremely poor, with a mortality of up to 87%. An urgent parathyroidectomy has been shown to decrease pain, improve wound healing and reduce the risk of amputation in these patients. It has also been associated with an increase in median survival.

Management

Renal transplantation remains the only definite treatment for secondary hyperparathyroidism. Other therapies are a bridge to this or aim to provide symptom relief. Standard management includes replacement of calcium and vitamin D and the reduction of phosphate levels by the use of phosphate binders. Treatment of this disease changed radically with the introduction of calcimimetic drugs, such as cinacalcet. Calcimimetics alter the set point of the calcium-sensing receptor, thereby reducing the constant stimulation of the parathyroid glands and lowering the PTH level. This obviously does not address the underlying renal disease. It remains controversial as to which patients may benefit from the use of calcimimetics and which patients may benefit from earlier surgical intervention. Indications for pursuing medical management include those patients who are deemed non-surgical candidates by reason of medical comorbidities. Similarly, where there is persistent or recurrent disease, the origin of which cannot be clearly elucidated, surgical management should be avoided. However, there are definite indications for surgical intervention in secondary hyperparathyroidism (*Table 56.3*), although these have been modified to reflect the current use, where available, of calcimimetics (*Table 56.4*).

There are a wide variety of operations that can be utilised for the management of secondary hyperparathyroidism, none of which appears significantly superior in terms of clinical outcomes (persistent or recurrent disease). These include a subtotal parathyroidectomy, a total parathyroidectomy with autograft or a total parathyroidectomy without autograft. Cryopreservation of resected tissue, where available, should be

TABLE 56.3 Indications for surgical intervention in secondary hyperparathyroidism.

Essential components
1. Persistently high serum level of intact PTH >500 pg/mL 2. Hyperphosphataemia (serum PO_4 >6 mg/dL) or hypercalcaemia (serum Ca >2.5 mmol/L or 10 mg/dL) which is refractory to medical management 3. Estimated volume of the largest gland >300–500 mm^3 or long axis >1 cm
Clinical findings
If patients have one of these symptoms, parathyroidectomy should be recommended: • Severe osteitis fibrosa with associated high bone turnover • Subjective symptoms (bone and joint pain, arthralgia, muscle weakness, irritability, pruritus, depression) • Progressive ectopic calcification • Calciphylaxis • Progressive reduction in bone mineral content • Anaemia resistant to ESA • Dilated cardiomyopathy/cardiac failure

ESA, erythropoietin-stimulating agent; PTH, parathyroid hormone.

J F Heremans, 1927–1975, Professor of Medicine, Catholic University of Louvain, Belgium.
Karl Schmid, 1920–2009, Biochemist, Boston Medical Center, Boston, MA, USA.

TABLE 56.4 Proposed indications for surgical management of secondary hyperparathyroidism (SHPT) in the era of calcimimetics.

- When SHPT is refractory to vitamin D replacement or vitamin D analogues and prolonged survival is anticipated
- Severely impaired quality of life owing to either SHPT or intolerance to calcimimetics
- When sufficient reduction in parathyroid hormone cannot be achieved with use of calcimimetics
- Thyroid surgery is also required (thyroid carcinoma)

performed in cases of significant postoperative hypocalcaemia. The first two procedures are most widely accepted and the type of operation performed depends upon the surgeon.

A subtotal parathyroidectomy is where three and a half parathyroid glands are excised, with the remnant being marked with a non-absorbable stitch to facilitate identification in the event of recurrent disease. A biopsy of the final gland that is to be left *in situ* is mandatory to confirm the presence of residual parathyroid tissue. Ideally an inferior gland is left *in situ* to facilitate reoperative surgery and minimise potential damage to the recurrent laryngeal nerve in that setting (***Figure 56.10***). A total parathyroidectomy with a forearm autograft involves removal of all parathyroid tissue in the neck, with reimplantation of a small amount of morcellated tissue within a pocket formed in the brachioradialis muscle. Overall, regardless of the operative approach utilised the cure rate ranges between 90% and 96%, with similar complication rates. A randomised study looking at 40 patients who underwent either a subtotal or total parathyroidectomy with autotransplant demonstrated no significant difference between the two operations in terms of efficacy and recurrence rate (Rothmund *et al.*, 1991).

The response to surgical intervention is often dramatic. The biochemical parameters may resolve almost immediately and appear to be sustained for up to 3 years postoperatively. Patients subjectively report improvements in the symptoms of secondary hyperparathyroidism, including bone pain, pruritus, fatigue and depression. Finally, bone metabolism is improved with an approximate 10% increase in trabecular bone, with almost immediate suppression of bone resorption and acceleration of new bone formation.

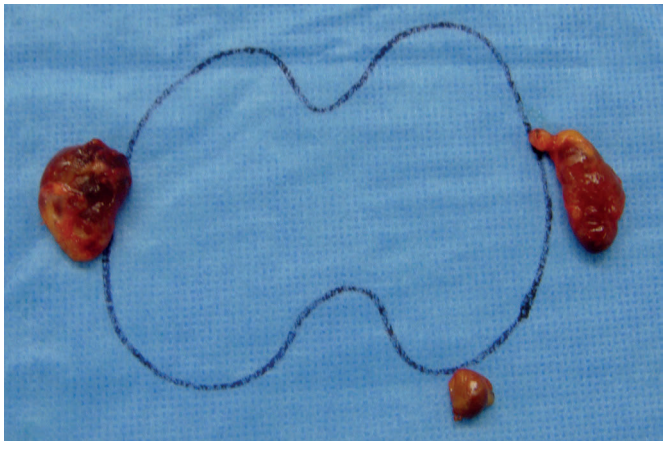

Figure 56.10 Subtotal parathyroidectomy for parathyroid hyperplasia. Right inferior gland biopsied and half left *in situ*.

Summary box 56.2

Secondary hyperparathyroidism

- Primarily due to underlying chronic kidney disease
- Associated with parathyroid hyperplasia
- Diagnosis is made biochemically with a low or normal calcium and an elevated PTH. High phosphate levels and low vitamin D levels are seen
- No localisation studies are required
- Mainstay of treatment is renal transplantation. Medical management with calcium and vitamin D replacements and phosphate binders is a bridge to transplantation
- Use of calcimimetics has reduced the requirement for surgical intervention
- Subtotal parathyroidectomy remains the surgical intervention of choice when indicated

TERTIARY HYPERPARATHYROIDISM

Tertiary hyperparathyroidism is a persistent autonomous hypercalcaemic hyperparathyroidism occurring after kidney transplantation. A number of proposed factors may prevent involution of the hyperplastic parathyroid glands following resolution of the underlying renal impairment. These include impaired graft function, non-suppressible PTH secretion, slow involution of enlarged glands or insufficient calcitriol conversion by the transplanted kidney.

The biochemical diagnosis is confirmed by an elevated total or ionised calcium, with an associated elevated or unsuppressed PTH and a reduced phosphate occurring at least 1 year post renal transplantation. Differentiation from PHPT can be difficult. Fewer than 1% of patients with tertiary hyperparathyroidism will require surgical intervention (***Table 56.5***). The only new evidence for intervention is the presence of nodular hyperplasia of the glands themselves. Traditionally, localisation studies or imaging of the neck was not indicated in tertiary hyperparathyroidism. However, increasing knowledge of the clonal nature of gland hyperplasia suggests that where there is a nodule within the parathyroid with a volume of tissue greater than 500 mm^3, then resolution of electrolyte abnormalities is unlikely.

TABLE 56.5 Indications for surgical intervention in tertiary hyperparathyroidism.

- Subacute severe hypercalcaemia (>3 mmol/L)
- Impaired graft function
- Nodular hyperplasia of the parathyroid gland(s)
- Progressive symptoms (>2 years following transplantation)
  - Worsening bone disease (pain, fracture, bone loss)
  - Renal stones/nephrocalcinosis
  - Soft-tissue or vascular calcifications

The use of calcimimetics in tertiary hyperparathyroidism remains controversial and has not been approved for this indication. However, isolated reports have documented control of hypercalcaemia with minimal side effects in individual patients. Surgical intervention remains the definitive management strategy. Subtotal parathyroidectomy or total

parathyroidectomy with autotransplantation are acceptable surgical options. The majority of endocrine surgeons will opt for a subtotal parathyroidectomy in this setting, leaving a gland approximately four times normal in volume to minimise postoperative complications. Total parathyroidectomy without an autograft is not a treatment option because of the postoperative and persistent difficulties in managing the associated hypocalcaemia.

Summary box 56.3

Tertiary hyperparathyroidism

- Persistent autonomous hypercalcaemic hyperparathyroidism occurring after kidney transplantation
- Diagnosis is made by demonstrating an elevated total or ionised calcium with an associated elevated or unsuppressed PTH and a reduced phosphate occurring at least 1 year post renal transplantation
- Localisation studies are not required but a focused neck ultrasonography may confirm the presence of nodular enlargement
- Surgical intervention remains the mainstay of treatment and involves a subtotal parathyroidectomy

PARATHYROID CARCINOMA

Parathyroid carcinoma is a rare malignancy occurring in approximately 1% of cases of PHPT, with an estimated prevalence of 0.005% of all cancers. While the aetiology remains unclear, recent advances in molecular biology suggest that there may be an underlying genetic basis. Currently, a history of previous neck irradiation remains the only known environmental risk factor. However, given that it can arise in patients with end-stage renal disease as well as in those with MEN type 1, malignant transformation in hyperplastic glands may also occur.

A significant proportion of patients (>10%) with a parathyroid carcinoma will have HPT-JT. The underlying mutation is in the *HRPT2/CDC73* gene at chromosome 1q21–q31, a tumour suppressor gene that encodes the protein parafibromin. Parafibromin is involved in the regulation of cellular transcription and histone modification. *HRPT2* mutations, leading to inactivation of parafibromin, are therefore an important contributor to the pathogenesis of parathyroid carcinoma. Similarly, up to 18% of patients with a parathyroid carcinoma will have an inactivating mutation of the *PRUNE2* gene, located on chromosome 9q21.2. This is a tumour suppressor gene that encodes the RAS homologue family member A, leading to suppression of oncogenic cellular transformation.

Parathyroid carcinoma remains difficult to diagnose preoperatively as it biochemically resembles PHPT. There are, however, a number of suggestive features. First, the diagnosis is typically made a decade earlier, with an equal gender preponderance when compared with PHPT. Second, a greater proportion of these patients will be symptomatic at presentation. A palpable neck mass is found in 36–52% of patients with parathyroid carcinomas but rarely (<5%) in cases of PHPT. Finally, the biochemical abnormalities tend to be exaggerated with an average total calcium of between 3.75 and 3.97 mmol/L and a PTH level 5–10 times the normal range.

The leading cause of morbidity and mortality from parathyroid carcinoma is hypercalcaemia due to inappropriate PTH secretion. Treatment is focused on controlling hypercalcaemia and removal of the carcinoma where possible. Surgery remains the mainstay of treatment for primary presentations and locally recurrent disease. Complete resection of the tumour, avoiding spillage, is vital in preventing seeding and thus recurrent disease. En bloc resection of the tumour, associated thyroid lobectomy and central neck dissection remain controversial.

Complete R0 resection was thought to provide the only means of a cure. However, a number of recent studies have failed to demonstrate an improvement in local recurrence rates with such comprehensive resection. Adjuvant chemotherapy has not been shown to confer a disease-free or overall survival benefit. Use of external beam radiotherapy should be considered on an individual basis. Traditionally, it has not been deemed effective, but more recent single-institution case series challenge this assumption. It may be considered where it is difficult to achieve a complete surgical resection or in patients with multifocal recurrent soft-tissue deposits.

Histological confirmation of a parathyroid carcinoma remains difficult. The World Health Organization criteria (2017) for the diagnosis of a parathyroid carcinoma emphasise the need for definite invasion of the surrounding soft tissue and/or metastatic disease. The classical description that included trabecular architecture, mitotic figures, thick fibrous bands and capsular and vascular invasion is largely non-specific. New molecular markers may aid the diagnosis and stratify patients for more intensive follow-up (***Figure 56.11***). Immunohistochemical evidence of downregulation of parafibromin has a sensitivity of 67% and a specificity of 100% for detecting parathyroid carcinoma and the protein gene product 9.5 (PGP 9.5). Parafibromin immunohistochemistry may be used with immunohistochemistry for PGP 9.5. This is a protein encoded by ubiquitin carboxyl-terminal esterase LI. It is upregulated in parathyroid carcinoma and has a sensitivity of 78% and a specificity of 100%. All parafibromin-negative and PGP 9.5-positive tumours should be considered for genetic screening.

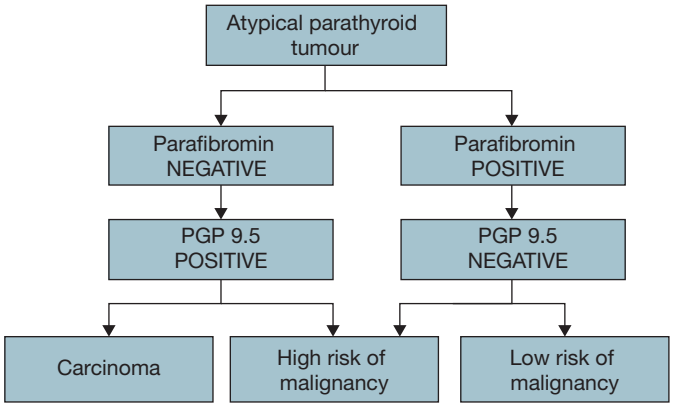

Figure 56.11 Proposed decision tree for atypical parathyroid tumours using parafibromin and PGP 9.5 immunohistochemistry.

Parathyroid carcinoma is an indolent but progressive disease. Metastatic spread can occur to the lungs, liver and bones. Recurrence rates range from 33% to 80% and it typically occurs in the first 3 years. Overall survival is reported to be 85–90% at 5 years and 49–77% at 10 years.

Summary box 56.4

Parathyroid carcinoma

- Accounts for approximately 1% of all cases of PHPT
- A history of previous neck irradiation remains the only known environmental risk factor
- The tumours remain difficult to diagnose preoperatively as they biochemically resemble PHPT
- Treatment is focused on controlling hypercalcaemia and removal of the carcinoma where possible
- Surgery remains the mainstay of treatment for primary presentations and locally recurrent disease. Complete resection of the tumour avoiding spillage is vital in preventing seeding and thus recurrent disease

PERSISTENT HYPERPARATHYROIDISM

Persistent hyperparathyroidism is defined as an elevated calcium within 6 weeks of surgical intervention. For all parathyroid operations (minimally invasive parathyroidectomy [MIP] and bilateral exploration) the rate of persistent hypercalcaemia is approximately 6% in sporadic disease and between 16% and 20% in hereditary disease. It usually arises as a result of a technical error during the first operation because of either a missed adenoma or asymmetrical disease. When this occurs all preoperative biochemistry, radiological imaging, intraoperative findings and pathology must be carefully reviewed. If reoperation is appropriate, repeat imaging of the neck and mediastinum is required (sestamibi, ultrasonography and 4D-CT scanning). Surgical intervention can be straightforward where there are intact tissue planes, such as following a minimally invasive parathyroidectomy. Complications, including recurrent laryngeal nerve damage and permanent hypocalcaemia, are increased when extensive previous dissection has occurred and the patient must be consented appropriately.

RECURRENT HYPERPARATHYROIDISM

Recurrent hyperparathyroidism is defined as hypercalcaemia occurring 6 months after surgery but with an intervening period of normocalcaemia. Common causes include missed pathology at the first operation; hyperplasia in remaining or autotransplanted tissue; parathyromatosis; or, very rarely, the development of a second parathyroid adenoma. Parathyromatosis refers to disseminated parathyroid tissue within the soft tissues of the neck and superior mediastinum owing to rupture of the parathyroid gland during the primary surgery. A definitive indication for surgical intervention must be present prior to embarking on localisation studies. Surgical intervention will be guided by the radiological imaging. Complication rates of recurrent laryngeal nerve damage and permanent hypocalcaemia are higher in reoperative surgery.

FURTHER READING

Agarwal A, Mishra AK, Lombardi CP, Raffaelli M. Applied embryology of the thyroid and parathyroid glands. In: *G.W. Randolph surgery of the thyroid and parathyroid glands*. Philadelphia, PA: Saunders, 2013: 15–24.

Barczyński M, Bränström R, Dionigi G, Mihai R. Sporadic multiple parathyroid gland disease – a consensus report of the European Society of Endocrine Surgeons. *Langenbecks Arch Surg* 2015; **400**(8): 887–905.

Bilezikian JP, Brandi ML, Eastell R *et al.* Guidelines for the management of asymptomatic primary hyperparathyroidism: summary statement from the Fourth International Workshop. *J Clin Endocrinol Metab* 2014; **99**: 3561–9.

Carneiro-Pla D, Pellitteri PK. Intraoperative PTH monitoring during parathyroid surgery. In: *G.W. Randolph surgery of the thyroid and parathyroid glands*. Philadelphia, PA: Saunders, 2013: 605–12.

Certani F, Pardi E, Marcocci C. Update on parathyroid carcinoma. *J Endocrinol Invest* 2016; **39**(6): 595–606.

Cheung K, Wang TS, Farrokhyar F *et al.* A metaanalysis of preoperative localisation techniques for patients with primary hyperparathyroidism. *Ann Surg Oncol* 2012; **19**(2): 577–83.

Howell VM, Gill A, Clarkson A *et al.* Accuracy of combined protein gene product 9.5 and parafibromin markers for immunohistochemical diagnosis of parathyroid carcinoma. *J Clin Endocrinol Metab* 2009; **94**(2): 434–41.

Iacobone M, Carnaille B, Palazzo FF, Vriens M. Hereditary hyperparathyroidism – a consensus report of the European Society of Endocrine Surgeons. *Langenbecks Arch Surg* 2015; **400**(8): 867–86.

Jeong HS, Dominguez AR. Calciphylaxis: controversies in pathogenesis, diagnosis and treatment. *Am J Med Sci* 2016; **356**(1): 217–27.

Krakauer M, Wieslander B, Myschetzky PS *et al.* A prospective comparative study of parathyroid dual-phase scintigraphy, dual-isotope subtraction scintigraphy, 4D-CT, and ultrasonography in primary hyperparathyroidism. *Clin Nucl Med* 2016; **41**(2): 93–100.

Mihai R, Simon D, Hellman P. Imaging for primary hyperparathyroidism – an evidence-based analysis. *Langenbecks Arch Surg* 2009; **394**(5): 765–84.

Pitt SC, Sipple RS, Chen H. Secondary and tertiary hyperparathyroidism: state of the art surgical management. *Surg Clin North Am* 2009; **89**(5): 1227–39.

Rodgers SE, Hunter GJ, Hamberg LM *et al.* Improved pre-operative planning for directed parathyroidectomy with 4-dimensional computed tomography. *Surgery* 2006; **140**(6): 932–40.

Rothmund M, Wagner PK, Schark C. Subtotal parathyroidectomy versus total parathyroidectomy and autotransplantation in secondary hyperparathyroidism: a randomized trial. *World J Surg* 1991; **15**(6): 745–50.

Silverberg SJ, Clarke BL, Peacock M *et al.* 2014. Current issues in the presentation of asymptomatic primary hyperparathyroidism. *Proc Fourth Int Workshop* 2014; **99**: 3580–94.

Walker DM, Silverberg SJ. Primary hyperparathyroidism. *Nat Rev Endocrinol* 2018; **14**(2): 115–125.